

Rectovaginal Fistula Complicated by Retained Vaginal Foreign Body: A Case Report

SHARMA NALINI¹, KOTHUNI CHRISTINA CHAKRE², DONKUPAR KHONGWAR³, DONBOKLANG LYSNER⁴, AHANTHEM SANTA SINGH⁵



ABSTRACT

Foreign bodies in the genital tract are rare but can be found in females of all ages. Objects inserted vaginally may be for therapeutic purposes, accidental placement, and sometimes even for sexual gratification. Non therapeutic objects commonly seen include tampons, bottle caps, sex toys, and, rarely, metallic objects of various shapes and sizes. The authors report a case of a 40-year-old widowed woman, with no living children, presenting with foul-smelling vaginal discharge and passage of stool per vagina. Upon examination, a retained vaginal foreign body was noted intravaginally, complicating as a rectovaginal fistula, necessitating emergency laparotomy and requiring a colostomy. Long-retained objects are known to cause excessive foul-smelling discharge and can lead to serious complications such as lacerations, pelvic inflammatory disease, fistulas, fibrosis, and even death. Therefore, patients should seek medical attention and be treated promptly to prevent any complications.

Keywords: Colostomy, Impacted vaginal foreign body, Laparotomy, Vaginal discharge

CASE REPORT

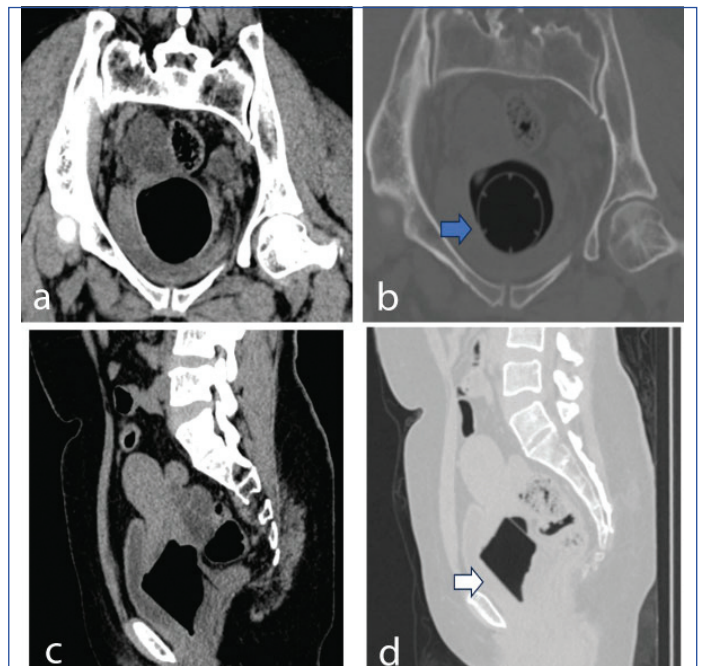
A 40-year-old presented to the surgical outpatient department with abdominal pain, foul-smelling vaginal discharge, and passage of stool from the vagina for a duration of 15 days. The patient was referred to the Gynaecological Department with a suspected impacted foreign body intravaginally. She had been married for five years but was now a widow with no living children. She lives with her mother, and no significant history of mental illness or chronic illness was found. During examination, she was uncooperative, and therefore a proper history could not be obtained. However, no signs of psychological/psychiatric instability or physical assault or abuse were noted. In the general physical examination, her pulse rate was elevated, but other parameters were within normal limits.

During the vaginal examination, a hard, non collapsible cylindrical object of approximately 4×4 cm was felt in the upper part of the vagina, with stool staining over the examining finger and a defect felt in the posterior vaginal wall communicating with the rectum. During the speculum examination, foul-smelling discharge with stool soiling over the vaginal canal was found. The vaginal mucosa appeared congested, inflamed, and oedematous, with a laceration in the upper third of the posterior vaginal wall. Due to the severe pain experienced by the patient, further examination was abandoned. During the rectal examination, a fistula in the upper anal canal was felt, and a hard, non collapsible, palpable foreign body was noted in the vagina through the defect.

The patient was immediately admitted, and intravenous antibiotics were initiated. All routine blood tests were performed. An urgent pelvic Computed Tomography (CT) scan revealed a cylindrical foreign body of approximately 4.5×3.5 cm in the upper vaginal canal, with the proximal end indenting the posterior wall of the bladder, resulting in a rectovaginal fistula [Table/Fig-1a-d].

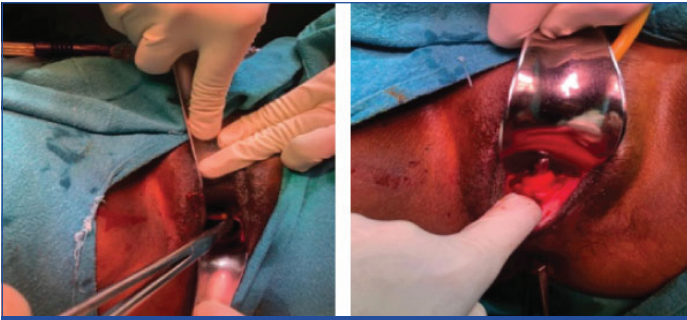
An emergency exploration under anaesthesia was decided upon in consultation with the departments of general surgery and urology due to the patient's severe pain. Under general anaesthesia, the patient was positioned in a lithotomy, and the vaginal cavity was adequately exposed for examination.

During the speculum examination, a purple-coloured plastic object with a sharp, open rounded border of approximately 4 cm in diameter was visualised in the upper part of the vagina [Table/Fig-2], with a defect in the posterior vaginal wall of approximately 3×3 cm, suggestive of a rectovaginal fistula [Table/Fig-3]. The foreign body was extracted using long artery forceps [Table/Fig-4]. Upon rectal examination, a rectovaginal fistula of approximately 3×3 cm, almost 6 cm from the anal verge, was noted [Table/Fig-3].



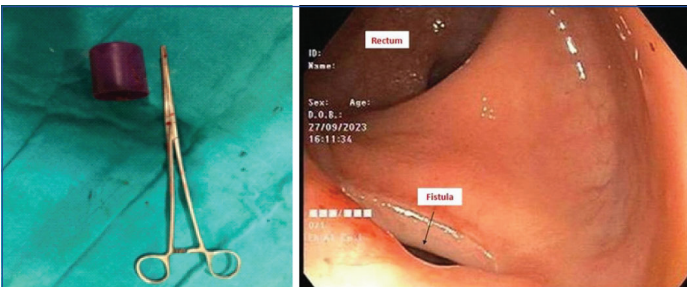
[Table/Fig-1]: Non Contrast Computed Tomography (NCCT) images cylindrical plastic foreign body with small internal teeth noted in vaginal canal indenting the posterior wall of the urinary bladder. Foreign body becomes apparent, the window Width (W) and Center (C) Coronal images (b compared to a), Sagittal images (d compared to c). Blue arrow- Apparent foreign body in coronal plane, white arrow -Apparent foreign body in Sagittal plane.

A decision was made to perform a diversion colostomy due to a contaminated, infected wound with inflamed mucosa and



[Table/Fig-2]: Impacted foreign body with sharp rounded edges.
[Table/Fig-3]: Rectovaginal fistula. (Images from left to right).

unprepared bowel. Following the procedure, a psychiatric evaluation was conducted, revealing no significant history, and the patient denied engaging in acts of sexual gratification or perversion. The patient was discharged on postoperative day 8 with a colostomy bag and was advised to follow-up after one month for the repair of the fistula and closure of the colostomy. After one month of follow-up, a colonoscopy was performed, revealing a clean, fibrosed, healed fistula [Table/Fig-5].



[Table/Fig-4]: Extracted foreign body using long artery forceps.
[Table/Fig-5]: Colonoscopy showing rectovaginal fistula. (Images from left to right).

DISCUSSION

Reproductive tract foreign bodies have been reported and observed, although they are a rare occurrence. Common reasons for insertion foreign bodies into the genital system include sexual curiosity, autoerotic stimulation, or during invasive procedures [1]. The objects discovered vary among age groups. An intravaginal foreign body can either remain asymptomatic for an extended period or be quickly detected through clinical signs. Symptoms depend on the duration of presence but more importantly on the nature and size of the foreign body [2]. Foreign bodies in the vagina can lead to various complications such as injuries that perforate the vagina, potential migration into the bladder causing peritonitis, pelvic adhesions, and the development of fistulas connecting to the bowel, bladder, uterus, and vagina [3]. Due to the association with sexual gratification, these patients feel ashamed and thus often provide an inaccurate history of foreign body insertion. Typically, the history is only obtained after the discovery of a fistula. Such cases are more commonly observed in children than in adult females [4,5].

The most common cause of rectovaginal fistula is obstetric injury following prolonged labour. Other common causes include Crohn's disease, advanced pelvic malignancies following pelvic radiation, or post-pelvic surgery [6]. Vaginal foreign bodies account for 4% of gynaecological complaints in prepubertal girls [7]. When foreign bodies remain in place for an extended period, they can lead to various issues, including infection, pelvic peritonitis, abscesses, vesicovaginal and rectovaginal fistulas, urinary incompetence, and impaction due to scarring and fibrosis [8-10].

Attempts at self-extraction can result in tissue damage, leading to infections and fistulas. Patients may feel embarrassed and may attempt self-removal rather than seeking medical advice [11]. The possibility of child sexual abuse should always be considered when dealing with the paediatric age group. In adults, various reasons may be considered,

including therapeutic approaches in gynaecological and obstetrical management, sexual gratification, and mental instability.

Diagnosis is based on a detailed history, clinical and gynaecological examinations, and radiological assessments [10]. The patient's diagnosis was facilitated by clinical examination aided by radiological intervention. Magnetic Resonance Imaging (MRI) is considered the best technique for evaluating vaginal foreign bodies in young children [12]. However, it may not always be available or conclusive. In the patient, a CT scan was performed, revealing a sharp rounded edge of the foreign body that had cut through the posterior vaginal wall, resulting in the rectovaginal fistula.

Due to the unique complications associated with foreign bodies, a multidisciplinary team approach is necessary for optimal outcomes and patient management. Management can be conservative or surgical depending on the identified object and associated pathology. Objects located in the lower portion of the vagina or near the introitus may be removed by gently separating the labia after a thorough examination with the assistance of forceps in the emergency department [13]. Before removal, it is important to rule out any injury to adjacent structures and tissues that may arise from deeply impacted foreign bodies.

In the present case, the foreign body was successfully retrieved under general anaesthesia through local examination. A colostomy was performed as an immediate treatment without repairing the fistula. A study conducted by Ojengbode OA et al., describes a one-stage repair of the fistula without a colostomy [14]. However, in the present case, fistula repair was delayed until four weeks later due to a dirty, contaminated wound with an unprepared and inflamed bowel. A similar report of rectovaginal fistula complicated by a retained colpotomy cup, where the foreign body was removed and repaired with an ileostomy without any complications, underwent takedown ileostomy after three months of the primary surgery [15]. Vaginoscopy with a 4 mm hysteroscope under general anaesthesia is highly useful for detection and treating vaginal foreign bodies [16], especially in paediatric patients, as successfully managed and reported by Yildiz S et al., [17].

After thorough history-taking and close observation of the patient, the authors suspected that this unusual complication may be linked to the patient's state of sexual gratification and autoeroticism (though the patient did not admit to this). A similar case involving vaginal foreign body autoeroticism was reported by Bansal A et al., where a foreign body was found piercing through the anterior vaginal wall and posterior bladder. It was removed using cystoscopy, with the foreign body known to have been inserted due to the patient's erotic stimulation [18].

CONCLUSION(S)

Foreign objects in the reproductive tract can be encountered and found in females of all age groups. Early presentation by the patient, a detailed history, and clinical examination can help detect the presence of a foreign body. However, imaging modalities may be necessary for diagnosis to prevent and avoid life-threatening complications. Patients should be counselled to prevent further recurrence of similar events.

REFERENCES

- [1] Johnin K, Kushima M, Koizumi S, Okada Y. Percutaneous transvesical retrieval of foreign bodies penetrating the urethra. *J Uro.* 1999;161(3):915-16.
- [2] Diaouga HS, Yacouba MC, Rahamatou MG, Idi N, Nayama M. Vesico-vaginal and rectovaginal fistula and death caused by a vaginal foreign body in a body packer. *Open J Obstet Gynaecol.* 2022;12(10):1056-61.
- [3] Panda S, Das A, Das R, Sharma N, Jante V. An unusual case of retained foreign body in the vagina with vaginal fibrosis. *Cureus.* 2022;14(1):e20956. Doi: 10.7759/cureus.20956.
- [4] Meniru GI, Moore J, Thomlinson J. Aerosol cap and rectovaginal fistula: Unusual findings at routine cervical smear. *Int J Gynaecol Obstet.* 1996;52(2):179-80.

- [5] Wankrim B, Haouss AE, Barjani F, Dahami Z, Moudouni MS, Sarf I. Combined vesicovaginal and rectovaginal fistulas associated with a vaginal foreign body. *Afr J Urol*. 2009;15(186-188).
- [6] Iwamuro M, Hasegawa K, Hanayama Y, Kataoka H, Tanaka T, Kondo Y, et al. Enterovaginal and colovesicle fistulas as late communications of pelvic radiotherapy. *J Gen Fam Med*. 2018;19(5):166-69.
- [7] Di Meglio G. Genital foreign bodies. *Pediatr Rev*. 1998;19(1):34.
- [8] Chopra BS, Singh Y, Magon N. A case of intravaginal foreign body. *Med J Armed Forces India*. 2010;66(3):266-68.
- [9] Biswas A, Das HS. An unusual foreign body in the vagina producing vesicovaginal fistula. *Indian Med Assoc*. 2002;100(4):257-59.
- [10] Picurelli L, Lopez Olmos J, Sendra A. Vesicovaginal fistula caused by foreign body in the vagina. *Actas Urol Esp*. 1997;21:511-12.
- [11] Ornellass AA, Waintrub S, Carvalho J, Koifman N, Bullos S. Fistule vesicovaginal apres ablation dun corps estranger intra-vaginal negligie. *Progres en Urlogie*. 2006;16:502-04.
- [12] Kihara M, Sato N, Kimura H, Kamiyama M, Sekiya S, Takano H. Magnetic resonance imaging in the evaluation of vaginal foreign bodies in a young girl. *Arch Gynecol Obstet*. 2001;265(4):221-22.
- [13] Benjamin F, Guillaume AJ, Chao LP. Vaginal smuggling of illicit drug: A case requiring obstetric forceps for removal of the drug container. *Am J Obstet Gynecol*. 1994;171(5):1385-87.
- [14] Ojengbede OA, Morhason-Bello IO, Shittu O. One stage repair of combined fistulas: Myth or reality? *Int J Gynaecol Obstet*. 2007;99(1):S90-93.
- [15] Kwon YS, You SK, Im KS, Kim SA. Rectovaginal fistula caused by retained colpotomy cup after surgery. *Clin Exp Obstet Gynecol*. 2016;43(2):271-73.
- [16] Golan A, Lurie S, Savig R, Glezerman M. Continuous-flow vaginoscopy in children and adolescents. *J Am Assoc Gynecol Laparasc*. 2000;7(4):526-28.
- [17] Yildiz Ş, Ekin M, Cengiz H, Dağdeviren H, Kaya C. Vaginal foreign body: Successful management with vaginoscopy. *J Turkish-German Gynecol Assoc*. 2013;14(1):46-47.
- [18] Bansal A, Kumar M, Kanodia G, Aeron R, Goel S. Unusual intravesical foreign body in young female migrated from vagina due to autoeritism. *Int Braz J Uro*. 2017;43(3):556-60.

PARTICULARS OF CONTRIBUTORS:

1. Additional Professor, Department of Obstetrics and Gynaecology, North Eastern Indira Gandhi Regional Institute of Health and Medical Sciences, Shillong, Meghalaya, India.
2. Senior Resident, Department of Obstetrics and Gynaecology, North Eastern Indira Gandhi Regional Institute of Health and Medical Sciences, Shillong, Meghalaya, India.
3. Additional Professor, Department of General Surgery, North Eastern Indira Gandhi Regional Institute of Health and Medical Sciences, Shillong, Meghalaya, India.
4. Additional Professor, Department of Radiology, North Eastern Indira Gandhi Regional Institute of Health and Medical Sciences, Shillong, Meghalaya, India.
5. Professor and Head, Department of Obstetrics and Gynaecology, North Eastern Indira Gandhi Regional Institute of Health and Medical Sciences, Shillong, Meghalaya, India.

NAME, ADDRESS, E-MAIL ID OF THE CORRESPONDING AUTHOR:

Kothuni Christina Chakre,
Punanamei Village P.O Mao Gate, Senapati District, Imphal-795150, Manipur, India.
E-mail: kothunichakre@gmail.com

PLAGIARISM CHECKING METHODS: [\(Lain H et al.\)](#)

- Plagiarism X-checker: Oct 21, 2023
- Manual Googling: Dec 26, 2023
- iThenticate Software: Jan 19, 2024 (9%)

ETYMOLOGY: Author Origin**EMENDATIONS:** 6**AUTHOR DECLARATION:**

- Financial or Other Competing Interests: None
- Was informed consent obtained from the subjects involved in the study? Yes
- For any images presented appropriate consent has been obtained from the subjects. Yes

Date of Submission: **Oct 20, 2023**Date of Peer Review: **Dec 21, 2023**Date of Acceptance: **Jan 21, 2024**Date of Publishing: **Mar 01, 2024**